



PATIENT

Ernie Canney

SPECIES

Feline

BREED

Sphinx

SEX

Male Neutered

AGE

11 months

WEIGHT

9.9lbs

INTERPRETED BY

Maggie Machen
Lamy, DVM
DACVIM (Cardiology)

IMAGING PERFORMED BY

Pamela Harrigan,
RDCS

HOSPITAL NAME

Mass Veterinary Services

REFERRING VET

Dr. Masloski

INVOICE

24633

DATE

6/7/22

PRESENTING CLINICAL SIGNS

History: Recheck echo. History perimembranous VSD with trivial left to right shunt noted on prior echocardiogram, 1/19/22 (Carley Saelinger, DVM, DACVIM-Cardiology). Ernie is presently doing well. He is eating well with normal activity. He is presently dealing with some skin and ocular issues. On exam today: NSR, grade III/VI parasternal murmur, PSS, lung fields clear, compressible thorax. BP: 160mmHg x 5. *Sedated with propofol for study.
-Pertinent previous echo findings: LA 1.10 cm; LA:Ao 1.32; LV 1.67 cm; Normal LA size; borderline LV dimension; small perimembranous VSD with trivial left to right shunting.

ECHOCARDIOGRAM FINDINGS

2D, m-mode, color flow and Doppler imaging is available.
Left ventricle: The LV diameter is normal with adequate myocardial function. LV wall thicknesses are normal. A perimembranous ventricular septal defect (VSD) is visualized. Trivial flow is seen crossing from left to right.
Left atrium: The left atrium is normal.
Mitral valve: The mitral valve is normal with no mitral regurgitation.
Aortic valve/aorta: The aortic valve is normal in morphology and mobility. Normal aortic outflow velocity; laminar flow. No aortic insufficiency.
Right ventricle: The RV appears normal.
Right atrium: Normal RA dimension.
Tricuspid valve: The tricuspid valve appears normal with trace tricuspid regurgitation.
Pulmonic valve/pulmonary artery: The pulmonic valve is normal in morphology and mobility. Trace pulmonic insufficiency. Normal RVOT velocity; laminar flow.
Pericardium/other: No pericardial or pleural effusion noted. No obvious cardiac masses.
Heart rhythm: ECG reveals a sinus rhythm with an average HR of 210bpm.

2-Dimensional Measurements

Ao diam (cm)	0.8
LA diam (cm)	1.2
LA:Ao (Swe)	1.5
IVS thickness (cm)	0.5
LVID diastole (cm)	1.4
PW thickness (cm)	0.5
LVID systole (cm)	0.65
FS (%)	54

Doppler Measurements

PV Vmax (m/s)	0.7
AoV Vmax (m/s)	1.2
MR Vmax (m/s)	NA
TR Vmax (m/s)	NA
TR PG (mmHg)	NA

INTERPRETATION OF THE FINDINGS

A perimembranous ventricular septal defect (VSD) is visualized, as was previously noted. No significant flow is seen crossing the shunt, indicating this is likely of little clinical significance. The overall cardiac dimensions and function are normal, and no additional issues are identified.

Given these findings, no medications are indicated.

Prognosis is open long-term.



PATIENT

Ernie Canney

SPECIES

Feline

BREED

Sphinx

SEX

Male Neutered

AGE

11 months

WEIGHT

9.9lbs

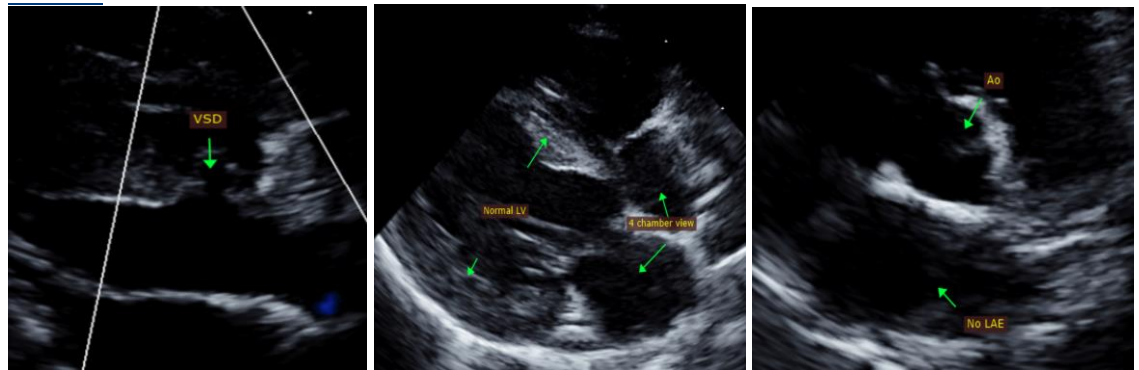
RECOMMENDATIONS

- No medications are indicated.
- No cardiac contraindication for general anesthesia. Mild IV fluid restriction is advised.
- Monitor for any breathing change, signs of a blood clot event, or collapse episodes going forward.

PLAN

- Recommend conservative monitoring with a recheck echocardiogram annually, sooner if any development of clinical signs.

IMAGES



INTERPRETED BY

Maggie Machen Lamy, DVM
DACVIM (Cardiology)

The information and recommendations provided are based on the images presented by the referring veterinarian. No evaluation can be communicated regarding pathology that was not visible in the image/video clips provided.

Thank you for this referral. This report was generated using transcription software, and minor dictation errors may be present. If the clinical or image interpretation does not parallel your findings or if I can be of any further assistance, please contact me.

IMAGING PERFORMED BY

Pamela Harrigan, RDCS

Maggie Machen Lamy, DVM
Diplomate of the American College of Veterinary Internal Medicine (Cardiology)
info@sonopath.com

HOSPITAL NAME

Mass Veterinary Services

Echocardiogram performed by: Pamela Harrigan, RDCS
Pet Animal Ultrasound Service (4paus.com)

REFERRING VET

Dr. Masloski

INVOICE

24633

DATE

6/7/22